

---

# Sporotrichosis in the Baixada Fluminense Region, Province of Rio de Janeiro, Brazil

Guilherme Barros Saiter<sup>1</sup>, Claudia Carreira de Barros<sup>2</sup>, Antonio Neres Norberg<sup>3,4,5</sup>, Fabiano Guerra Sanches<sup>4,6</sup>

<sup>1</sup>Medicine Academic of Souza Marques Medicine School – FTESM, Rio de Janeiro, Brazil

<sup>2</sup>APICE Hospital Dia, Rio de Janeiro, Brazil

<sup>3</sup>Souza Marques Medicine School – FTESM, Rio de Janeiro, Brazil

<sup>4</sup>UNIABEU/PROBIN University Center, Belford Roxo, Brazil

<sup>5</sup>Manhuaçu Management Sciences School – FACIG, Manhuaçu, Brazil

<sup>6</sup>Official physician of Brazilian Army, Rio de Janeiro, Brazil

## Email address:

guilherme.saiter@gmail.com (G. B. Saiter), guilherme.saiter@gmail.com (C. C. Barros), antonionorberg@gmail.com (A. N. Norberg), fab.gs@bol.com.br (F. G. Sanches)

## To cite this article:

Guilherme Barros Saiter, Claudia Carreira de Barros, Antonio Neres Norberg, Fabiano Guerra Sanches. Sporotrichosis in the Baixada Fluminense Region, Province of Rio de Janeiro, Brazil. *Science Journal of Public Health*. Vol. 5, No. 1, 2017, pp. 45-48.

doi: 10.11648/j.sjph.20170501.17

**Received:** October 3, 2016; **Accepted:** December 6, 2016; **Published:** January 18, 2017

---

**Abstract:** Sporotrichosis is a polymorphic disease caused by the fungus *Sporothrix schenckii*, which manifests mainly in the lymphocutaneous form, skin-fixed form, skin-disseminated form and sometimes with extra-skin form, affecting bones, joints, lungs and central nervous system. Objective: Investigate the occurrence of the disease in the population of Baixada Fluminense region. Material and methods: the lesion's material suggestive of sporotrichosis of 13 patients was collected and sent to a clinical pathology laboratory where it was grown in Petri dishes containing Sabouraud dextrose agar medium. The dishes were sealed and stored at room temperature. The obtained fungal growth was identified by analysis of the morphological characters. Result: The results confirmed the identity of *S. schenckii* of the 13 samples. Conclusions: lymphocutaneous form was the most frequent with lesions on the face and upper limbs. The contact with infected cats was considered the main mechanism of transmission of the etiologic agent among the studied patients. Treatment with itraconazole and potassium iodide was effective and well tolerated.

**Keywords:** *Sporothrix schenckii*, Sporotrichosis, Zoonosis (Source: MeSH: MeSH NLM)

---

## 1. Introduction

Sporotrichosis is a chronic disease caused mostly by traumatic implantation of *Sporothrix schenckii* fungus in the body. Usually the lesions are restricted to the skin, subcutaneous tissue and adjacent lymph vessels to the lesions. However, in some cases the fungus can spread to another organs or be primarily systemic when infection occurs by inhaling spores [1]. The disease is a significant public health problem in many countries due to the increasing human cases in recent years [2, 3, 4, 5]. It is a disease generally associated to the occupation, especially in the rural area, where people deals with land, and can affects people of both genders, of any age or ethnicity, regardless of individual

predisposing factors [6, 7]. Important information regarding the transmission of this etiologic agent is related to certain recreative activities and occupational as horticulture, floriculture, gardening, fishing, agriculture, hunting and logging. Mining is one of the activities over the years that have also been associated with the transmission or the sporotrichosis etiological agent. The disease is also considered zoonotic, since the transmission of the fungus can also occur by the bite or scratch of sick cats or asymptomatic carrier cats [5, 8, 10]. In cats, sporotrichosis has often a long-course with systemic involvement, progressing to severe disease, with difficult of treatment and progression to death in almost all cases. In cats, the most common clinical manifestations are fixed, lymphocutaneous and skin-

disseminated, usually accompanied by respiratory signs. Since 1997 the city of Rio de Janeiro and surrounding areas live an epidemic of the disease, most cases acquired through contact, bite, and scratch of infected cats [5, 11].

Sporotrichosis is a polymorphic disease and most often manifests in lymphocutaneous form, fixed form, skin-disseminated form, and sometimes extra-cutaneous, affecting bones, joints, lungs and central nervous system. This polymorphism does not depend on variations of the etiologic agents, but is associated with different immune responses of the host against the fungus. In immunocompromised patients, the lesions caused by the fungus tends to worsen and some studies show that most infected rates occurs in patients with immunodeficiencies [12, 13].

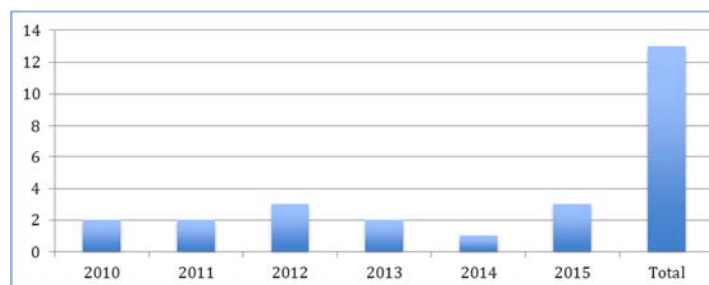
The most common form of sporotrichosis begins with an isolated nodular lesion at the site of inoculation of the etiological agent, usually chancroid and located on the hand, arm or leg. A few weeks after appears the primary lesion, other nodes may arise along the primary lesion and at this lymphatic drainage. Generally they ulcerate, present a serosanguineous exudate and cicatrize like a gum. The joint involvement manifests as pain and swelling of the affected joint, but without involvement of the adjacent skin. If not properly treated, the sporotrichosis continues to spread along the skin [1, 9].

Regarding the pathology, when the inoculation of the skin occurs, *S. schenckii* proliferates locally and induces an inflammatory response that produces ulceronodular injury. The infection often spreads through the subcutaneous lymph, resulting in cutaneous nodular chain lesions (ascending nodular lymphangitis). The extracutaneous clinical form is much less common than the skin disease. Joints and bones involvements are the most common forms of extracutaneous disease, and infections of the pulse, elbow, ankle and knee compounds the majority (80%) of these cases. Cutaneous sporotrichosis lesions are generally concentrated in the dermis or subcutaneous tissue. The periphery of the nodules is rampant pseudo-epitheliomatous. Some background yeast cells are surrounded by a spiculated and eosinophilic zone, and are called asteroid [1, 9].

Considering the clinical importance of this mycosis, this study aimed to record the cases of sporotrichosis diagnosed in the dermatology clinic of Apice Hospital Dia, neighborhood of Pavuna, São João de Meriti city, Baixada Fluminense region of the Province of Rio de Janeiro.

## 2. Material and Methods

Clinical samples of suggestive cases of sporotrichosis were



**Figure 1.** Frequency of sporotrichosis in the Baixada Fluminense region between 2010 and 2015 (simple frequency).

collected during the years 2010 to 2015 from patients attending the dermatology clinic of Apice Hospital Dia located in the city of São João de Meriti, province of Rio de Janeiro. All patients with ulcerated or gummy lesions suggestive of sporotrichosis were included in the sample. The material was collected with sterile swab and seeded in Petri dishes containing Sabouraud-dextrose-agar culture medium added with chloramphenicol to inhibit the growth of bacterial contaminants. The dishes were sealed with adhesive tape and kept at room temperature ( $\pm 25^{\circ}\text{C}$ ). The fungal growth was identified by macroscopic characteristics: filamentous colonies initially white forming a black halo which progressed until the total darkening of the colonies. Microscopic appearance: hyaline hyphae septated with oval conidia similar to a "daisy" form at the end of the conidiophore. Joining the macroscopic and microscopic characteristics, the definitive diagnosis was determined.

## 3. Results

All patients presented ulcerated or ulcerogomous lesions suspected of sporotrichosis on the face or upper limbs. The lesion's culture results showed 100% of positivity for the samples tested, confirming that the clinical characteristics corresponded to sporotrichosis in all cases.

**Table 1.** Distribution of the occurrence of sporotrichosis according to genus in Baixada Fluminense between 2010 and 2015.

Genus	Simple frequency	Percentual frequency	Absolute frequency
Male	4	30,77	0,31
Female	9	69,23	0,69
Total	13	100	1

Source: APICE Hospital Dia

**Table 2.** Frequency of sporotrichosis in Baixada Fluminense between 2010 and 2015.

Year	Simple frequency	Percentual frequency	Absolute frequency
2010	2	15,39	0,15
2011	2	15,39	0,15
2012	3	23,08	0,23
2013	2	15,39	0,15
2014	1	7,69	0,08
2015	3	23,08	0,23
Total	13	100	1

Source: APICE Hospital Dia

**Table 3.** Distribution of the occurrence of sporotrichosis according to age classes and gender in Baixada Fluminense between 2010 and 2015.

Age classes	Male	Female
10-19		1
20-29	1	1
30-39		1
40-49	1	1
50-59		3
60-69	1	1
70-79	1	1
Total	4	9

Analyzing the distribution by gender, sporotrichosis was predominant in woman, corresponding to 69.23% of the patients. Regarding the age classes, the distribution was practically uniform in all ages, with one case for each group.

## 4. Discussion

Human sporotrichosis has been reported in several cities of the Rio de Janeiro Province. Between 1997 and 2007, 1848 cases of the disease were diagnosed and treated in humans, 1287 of them recorded in the last four years. The frequency of sporotrichosis cases in the last four years represents twice as many relative cases as in the previous seven years [5]. According to Tavares-Silva *et al.* [5], the sociodemographic characteristics of the patients attended were predominantly women (66.9%), and in the age class between 21 and 60 years (67.5%). The disease was diagnosed in people of all ethnics, but predominant in white people, with prevalence in women, fact also observed in our study, in which 69.23% of the cases were in women. In a ten years research with the 1848 patients, 65% had cats in their home environment, and among them, 83.3% pointed the cat as a declared source of the infection. Regarding the geographic distribution of the disease, cases were recorded in 36 of the 92 cities (39%) which compound Rio de Janeiro Province. However, 95.13% of the cases were diagnosed in patients living in 11 cities of the metropolitan region. Rio de Janeiro city corresponds to 51% of the cases of sporotrichosis in the Province, followed by Duque de Caxias (20.62%), São João de Meriti (9.25%), Nova Iguaçu (5.3%), Nilópolis (3.9%), Belford Roxo 0.8%) and Mesquita (1.79%) [5]. Sporotrichosis in the metropolitan region of the Province of Rio de Janeiro has been evidenced in the last decade as an urban non-labor disease in localities where, according to official information, the conditions of infrastructure and sanitation are precarious. We agree with the mentioned authors while observing similar conditions in the region of our research.

The cases of sporotrichosis analyzed in this study were registered among people living at Baixada Fluminense region, which covers the area where the assisted patients live in the neighborhood of Pavuna, bordering Rio de Janeiro and São João de Meriti, the same region where Tavares-Silva *et al.* [5] recorded at least 95.66% of the cases of their research.

Sporotrichosis is not a frequently reported disease, and for this reason its prevalence is unknown, although it has been reported in several countries of the American continent:

United States of America, Mexico, Guatemala, Colombia, Peru and Brazil. In Asia: China, India, Japan. It also occurs in Australia. In the last century, many cases of the disease were reported in France [14, 15, 16]. These authors commented that the cases in Europe are decreasing, and nowadays the human sporotrichosis is rare in this continent.

In the opinion of Schubach *et al.* [17], the epidemic of sporotrichosis in the Province of Rio de Janeiro is characterized by zoonotic transmission in home environment, with the cat as the transmitter of the etiological agent. The authors isolated the fungus in 100% of feline cutaneous lesions, 62.2% of nasal cavities and 39.5% of cats' nails. The research carried out by these authors demonstrated the importance of the felines as a major source of contamination for other felines, as well as potential source of contamination for humans. In our research, all lesions were located on the patients' face and upper limbs, suggesting that the closeness while handling cats was the main source of infection.

Researchers Bernardes-Engelmann *et al.* [18] studied sporotrichosis in children and teenagers attended at the Pedro Ernesto University Hospital - UERJ, in the city of Rio de Janeiro, between 1997 and 2010. They commented that since 1997 the city of Rio de Janeiro, that presents an epidemic of zoonotic transmission of sporotrichosis and considered that the population of children and teenagers is more affected by close contact with diseased or asymptomatic fungus carrier cats. These authors diagnosed the disease in 37 patients and considered that contact with the cat was the main source of infection. The lymphocutaneous clinical form was predominant, and the sites most affected were the upper limbs and face, similar results found in our research. These results differ from those obtained in our study, in which all age groups were affected, but with a higher incidence among women aged 50-59 years.

Barros *et al.* [19] reported that sporotrichosis in the Province of Rio de Janeiro has taken epidemic proportions and was included in the list of mandatory noticeable diseases of the Province, since it has become an important public health problem.

## 5. Conclusions

In the studied population, all cases presented the lymphocutaneous clinical form and the lesions were on the face and upper limbs. Contact with infected cats was considered the main mechanism of transmission of the etiologic agent among the studied patients. The treatment with itraconazole and potassium iodide was effective and well tolerated, and it was administered until the total cure of the patients.

## References

- [1] Coura JR. Dinâmica das Doenças Infecciosas e Parasitárias. Rio de Janeiro, Ed Guanabara Koogan, 2015.

- [2] Schubach AO, Barros MBL, Wanke B. Epidemic sporotrichosis. *Curr Opin Infect Diss* 2008; 21: 129-133.
- [3] Barros MBL, Schubach TP, Coll TO, Gremião ID, Wanke B, Schubach AO. Esporotricose: a evolução e os desafios de uma epidemia. *Rev Panam Salud Pública* 2010; 27: 455-460.
- [4] Freitas DF, Valle AC, Almeida-Paes R, Bastos FI, Galhardo MC. Zoonotic sporotrichosis in Rio de Janeiro, Brazil. *Clin Infect Dis* 2010; 50: 453.
- [5] Tavares-Silva MB, Costa MMM, Torres CCS, Galhardo MCG, Valle ACF, Magalhães MAFM *et al.* Esporotricose urbana: epidemia negligenciada no Rio de Janeiro, Brasil. *Cad Saúde Pública* 2012, 28 (10): 1867-1880.
- [6] Lacaz C, Porto E, Martins J, Heins-Vaccari E, Melo N. *Tratado de Micologia Médica*. São Paulo, Ed Sarvier, 2002.
- [7] Almeida LGF, Almeida VGF. Uma revisão interdisciplinar da esporotricose. *Rev Eletrônica Estácio Saúde* 2015, 4 (2): 171-179.
- [8] Ramirez-Soto M, Lizarraga-Trujillo J, Ticona-Sanchez E, Carrion Leon O, Baroda-Lopez S. Perfil Clínico epidemiológico en una clínica de referencia en Abancay, Peru. *Rev Peru Epidemiol* 2012; 16 (2): 121-126.
- [9] Rubin E, Gorstein F, Rubin R, Schwarting R, Strayer D. *Rubin Patologia. Bases Clínico-Patológicas da Medicina*. Rio de Janeiro, Ed Guanabara Koogan, 2010.
- [10] Rodrigues AM, Melo-Teixeira M, Hoogs GS *et al.* Phylogenetic analysis reveals a high prevalence of *Sporothrix brasiliensis* in feline sporotrichosis outbreak. *PLoS Negl Trop Dis* 2013; 7; E 2281.
- [11] Xavier MO, Nobre MO, Junior DPS, Antunes TA, Nascente OS, Soria FBA *et al.* Esporotricose felina com envolvimento humano na cidade de Pelotas, Brasil. *Ciência Rural* 2004; 34 (6): 1961-1963.
- [12] Ramirez-Soto MC, Loayza-Calderón M. Esporotricosis polimórfica, un problema de salud pública que debemos valorar. *Acta Med Per* 2012; 29 (2): 128-131.
- [13] Morales LP, Lopez MI, Cherta OQ, Rodriguez IR. Aislamiento microbiológico de *Sporothrix schenckii* en un caso. *Rev Medsur* 2014; 12 (4): 662-669.
- [14] Rosa ACM, Scroferneker ML, Vettorato R, Gervini RL, Vettorato G, Webwe A. Epidemiology of sporotrichosis: a study of 304 cases in Brazil. *J Am Acad Dermatol* 2005; 52 (3): 451-454.
- [15] Barros MB, Almeida- Paes R, Schubach AO. *Sporothrix schenckii* and sporotrichosis. *Clin Microbiol Rev* 2011; 24: 633-654.
- [16] Chakrabarti A, Bonifaz A, Gutierrez-Galhardo MC, Mochizuki T, Li S. Global epidemiology of sporotrichosis. *Medical Microbiology* 2015; 53: 3-14.
- [17] Schubach TPM, Schubach AO, Reis RS, Cruzzi-Maya T, Blanco TC, Monteiro DF *et al.* *Sporothrix schenckii* isolated from domestic cats with and without sporotrichosis in Rio de Janeiro. *Mycopathology* 2002; 153: 83-86.
- [18] Bernardes-Engelmann AR, Lopes-Bezerra LM, Macedo PM, Orofino-Costa R. Esporotricose em crianças e adolescentes atendidos no HUPE-UERJ entre 1997 e 2010: estudo clínico epidemiológico. *Rev HUPE* 2012; 13 (1): 50-54.
- [19] Barros MBL, Schubach, AO, Schubach TM, Wanke B, Lambert-Passos SR. NA epidemic of sporotrichosis in Rio de Janeiro, Brazil: epidemiological aspects of a series of cases. *Epidemiol Infect* 2008; 136: 1192-1196.